
*Original Article***BOTOX INJECTION VERSUS LATERAL RECTUS MUSCLE SURGERY FOR TREATMENT OF BASIC EXOTROPIA****Esmail, A. & Nage, S. (*)**

Ophthalmology dept., Faculty of Medicine, Menoufia Univ., Egypt

*E-mail: doaa.mamdouh.marie@gmail.com

Received: 21/9/2022

Accepted: 3/11/2022

Doi: 10.21608/ejco.2022.280972

Abstract

Purpose: to evaluate Botox injection versus bilateral rectus muscle recession for treatment of basic exotropia. **Methods:** Of the 60 patients with basic exotropia included in a prospective comparative clinical study which conducted at outpatient's clinic of ophthalmology, Menoufia University Hospital during March 2021 till June 2022 were eligible for inclusion. A detailed history of strabismus, complete ophthalmologic and orthoptic assessment were done. **Results:** there were no significant differences between the studied groups regarding angle of squint pre and post-operative ($P=0.563$, 0.145 respectively). Also, angle of squint was significantly improved after operation than preoperative among Botox injection group (3.72 ± 1.96 vs 31.67 ± 6.64 , $P<0.001$), and patients with bilateral rectus muscle recession (2.89 ± 1.32 vs 32.56 ± 9.46 , $P<0.001$). **Conclusions:** In the treatment of basic exotropia, Botox injection is as effective as bilateral lateral recession.

Keywords: *Bilateral rectus muscle recession, Botox injection, Exotropia treatment, Squint angle***1. Introduction**

The most prevalent kind of strabismus encountered globally is exotropia. It is the eyes' outward tilt or turning away from the nose. The divergent deviation of the visual axis must remain consistent across all gaze positions to be considered a concurrent deviation [1]. Congenital, primary, sensory, and consecutive exotropia are the different types of concomitant exotropia [2]. In people whose vocations need extensive individual eye-to-eye contact, strabismus may also be physically unappealing and have a notable mental effect like decreased confidence. Having strabismus can harm relationships with family members as well [3]. The most

typical type of exotropia is intermittent. The surgical treatment of intermittent exotropia has been recommended using a variety of techniques. The two most common surgical procedures are bilateral lateral rectus recession and unilateral lateral rectus recession with medial rectus resection [2]. Although strabismus surgeons frequently perform these procedures, unilateral lateral rectus recession has also been documented. Its effectiveness has previously been contested, and the indicators of its efficacy are still debatable [4]. The neurotoxin known as Botox is made by the bacterium *Clostridium botulinum*. The use of Botox to treat

extraocular muscles was originally described in 1981 [5]. Scott et al. [6] concluded that when botulinum toxin A was used to cure strabismus, horizontal strabismus was more negatively impacted than vertical strabismus. Botox injection is a safe, effective, and noninvasive pharmaceutical alternative to surgery for strabismus, oculomotor paralysis, nystagmus, and other extraocular muscle dysfunctions, despite the transient negative effects of ptosis and diplopia [7]. Some forms of strabismus respond more favorably than others, such as those that coexist with a functional ipsilateral antagonist and normal muscular flexibility [8].

2. Methods

Of the 60 patients with basic exotropia included in a prospective comparative clinical study which conducted at outpatient's clinic of ophthalmology, Menoufia Univ. hospital during March 2021 till June 2022 were eligible for inclusion. After a quick and concise description of the study's objectives, the patient or the patient's legal guardian signed a written informed consent form. The Local Ethical Scientific Committee of the Menoufia Faculty of Medicine gave its approval to the study plan. The inclusion criteria were both sexes with basic XT, normal fundus, no other ocular

2.1. Pre-operative examination

The patients' records were analyzed to determine the review of the entire ophthalmologic and orthoptic system, including evaluation of visual acuity, extraocular muscle function, angle of deviation, final

2.2. Procedure

After a thorough preoperative diagnostic evaluation, inhalational anesthesia was administered to all patients, and the injection site was chosen in accordance with the normal anatomical site of the target muscle. The Botox dosage, which varied from 5 to 25 IU per muscle, was determined by the surgeon's discretion. All patients were followed up at 1 week, 1 month, 3 months, 6 months and 1 year following the injection. During each visit, the eye's deviation was recorded as esotropia, exotropia, or orthophoria. The degree of horizontal stra-

In contrast to exotropia, the medicine was found to be more beneficial in cases of esotropia with small to moderate angles than vertical abnormalities, or high angle deviations. If eye surgery was not advised, such as in cases of acute dysthyroid myopathy, botulinum toxin treatment was deemed appropriate. In cases of extraocular muscular palsy, the toxin could prevent contracture in the antagonistic muscle. It could be applied either intraoperatively or postoperatively as a surgical adjuvant [9]. So, we aimed to evaluate Botox injection versus lateral rectus muscle surgery for the treatment of basic exotropia.

pathology, no amblyopia, and no previous squint surgery and XT small and moderate angle that does not exceed 45 PD. The exclusion criteria were other types of XT, previous squint surgery; large angle exotropia and amblyopia were excluded from our study. Children who had an accurate diagnosis of IXT and a need for surgery might participate. The BTA injection group (Group A) and the standard surgery group were each given a group of subjects (Group B). We followed up on every instance for six months.

diagnosis, and available treatments. Using the prism and alternate cover test, variations in positions principal were measured at a distance of (6m) and close to (33cm) [10].

bismus that was still present at the final appointment was the primary determinant of success, allowing for the development of binocularity in young patients or cosmetically acceptable therapy in adults. Because a residual angle of 10 prism diopters (PD) or less is commonly regarded as a respectable outcome, we used this threshold in our experiment. As a result, at the final post-injection visit, failure signs included horizontal deviation or a residual angle of more than 10 PD.

2.3. Outcomes of the study

The main result was a comparison of the two groups' success rates (deviation between -10 and +10 PD) six months following the

2.4. Methods of statistical analysis

The results were tabulated and statistically analyzed using SPSS V.25 (IBM Corporation, 1 Orchard Rd, Armonk, NY 10504, USA). The descriptive statistics included the mean (x), median, and SD, while the

start of treatment. Change in deviation, visual function, and postoperative complications were all secondary outcomes.

analytical statistics included the chi-square test (2), Standard Student t-test (t), and Kruskal Wallis test (SD). A P value of 0.05 or less was used to determine if a statistic was significant.

3. Results

A CONSORT flow chart of the study population is shown in fig. (1) of the 67 patients diagnosed exotropia, five of them did not match the inclusion criteria, and two patients withdrew to take part. 60 patients agreed to participate in the trial and gave their approval. Final analysis

involved 60 patients with exotropia, 30 of whom had lateral rectus botox injections and another 30 who underwent bilateral rectus muscle recession. Each group was divided into two groups (males and females).

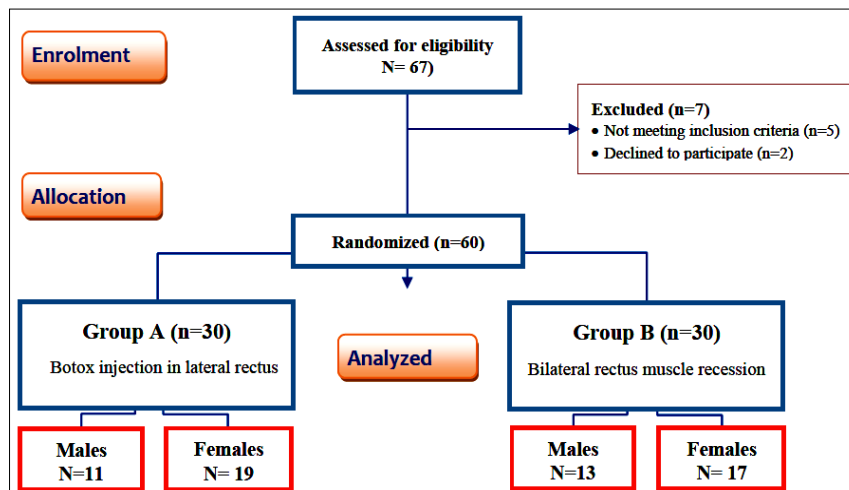


Figure 1: Flowchart of the studied exotropia.

3.1. Demographic data of the studied groups

A total of 60 patients showed that, there were no significant differences among Botox injection in lateral rectus (group

A) and surgery with bilateral rectus muscle recession (group B) regarding age and sex ($P > 0.05$), tab. (1).

Table 1: Demographic data of the studied groups.

Variables	Group A (n=30)	Group B (n=30)	Total (n=60)	t/X ²	P value
Age/year • Mean \pm SD • Range	15.17 \pm 5.48 5-25	17.17 \pm 8.51 4-30	16.12 \pm 7.46 5-30	t=1.082	0.284
Sex, no (%) • Male • Female	11 (36.67%) 19 (63.33%)	13 (43.33%) 17 (56.67%)	24(40%) 36(60%)	X ² =2.69	0.083

t: independent t-test. X²: Chi-square test. CI: Confidence interval for Mean.

Group A: patients with Botox injection in lateral rectus

Group B: patients under surgery with bilateral rectus muscle recession

3.2. Angle of squint pre and post-operative

Also, there were no significant differences between the studied groups regarding angle of squint pre and post-operative (P=0.563, 0.145 respectively), tab. (2).

Table 2: Angle of squint pre and post-operative among the studied groups.

Angle of squint	Group A (n=30)	Group B (n=30)	U	P value	95% CI		
					Mean diff.	Lower	Upper
Preoperative							
• Mean ±SD	29.63 ±8.31	30.87 ±8.13	0.581	0.563	-1.23	-5.48	3.01
• Range	18-45	2-8					
Postoperative							
• Mean ±SD	3.72±1.96	2.89±1.32	1.493	0.145	0.83	-0.30	1.97
• Range	18-45	2-5					

U: Mann-Whitney test, CI: Confidence interval for Mean.

Group A: patients with Botox injection in lateral rectus

Group B: patients with surgery with bilateral rectus muscle recession

3.3. Angle of squint

3.3.1. Group A

Additionally, angle of squint was significantly improved after operation compared before operation (3.72±1.96 vs 31.67±6.64) among Botox injection group, (P<0.001), tab. (3), and. figs. (2 & 3).

Table 3: Angle of squint before and after operation among group A.

Variables		Group A (n=30)					
		Mean ±SD	t	P value	Mean diff.	95%CI Lower	Upper
Angle of squint	Preoperative	31.67 ±6.64	22.336	<0.001*	27.94	25.30	30.58
	Postoperative	3.72 ± 1.96					

t: paired t-test. *Significant. CI: Confidence interval for Mean.

Group A: patients with Botox injection in lateral rectus

3.1.2. Group B

Also, angle of squint was significantly improved after operation compared before operation (2.89±1.32 vs 32.56±9.46) among patients with bilateral rectus muscle recession, (P<0.001), tab. (4), and figs. (2 & 3) shows that no significant different between the studied groups.

Table 4: Angle of squint before and after operation among group B.

Variables		Group A (n=30)					
		Mean ±SD	t	P value	Mean diff.	95%CI Lower	Upper
Angle of squint	Preoperative	32.56 ±9.46	14.219	<0.001*	29.67	25.26	34.07
	Postoperative	2.89 ±1.32					

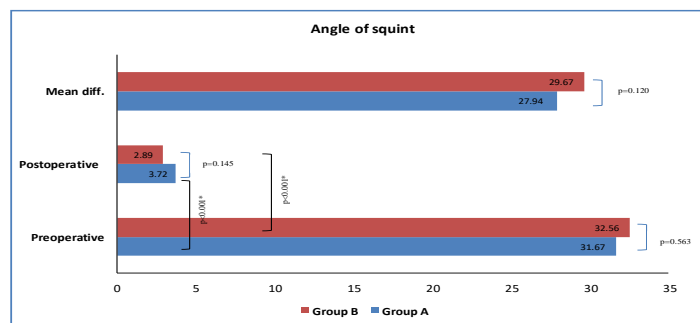


Figure 2: Mean changes of angle of squint among group A and B.



Figure 3: Four cases presentation (1 male and 3 female) improved postoperative compared preoperative with Botox injection and surgery in lateral rectus.

4. DISCUSSION

Some patients with strabismus might not be eligible for binocular surgery or could refuse it. Another alternative for these patients is a monocular treatment, which has certain advantages and can be done under peribulbar anaesthesia. The effectiveness of monocular surgery could be increased by better surgical results for common treatments. Theoretically, utilizing intraoperative coadjuvant botulinum toxin A could improve this. (BT). There are not many reports on the intraoperative injection of BT. [11] Botulinum toxin (Botox) therapy, a well-known treatment option for strabismus, is typically used to cure esotropia. Exotropia is a common kind of strabismus; however it is not yet known if Botox can treat it. [12] Botox injection is a noninvasive, safe, and effective pharmacological therapeutic option for strabismus, oculomotor paralysis, nystagmus, and other extraocular muscle dysfunctions. Certain types of strabismus respond better than others, such as concurrent strabismus with appropriate muscular flexibility and a functioning ipsilateral antagonist. Depending on the patient's age, level of extraocular muscle contracture or flexibility, and kind of strabismus, the onset of action typically takes between 24 and 72 hours, peaks at

around 10 days, and subsides after two to three months. [13] In order to cure simple exotropia, we set out to compare Botox injection to lateral rectus muscle surgery. The current investigation demonstrated that all the investigated patients had exotropia prior to surgery. However, there were no notable variations amongst the groups examined. In study by Al Hemaidi et al. [8] evaluated how well exotropia could be treated with a Botox injection. In their investigation, sensory exotropia was the most common diagnosis, accounting for 30.9% of the strabismus cases. Sequential exotropia was the second most common diagnosis among the individuals, behind sensory exotropia. 46.4% of participants had never had surgery, and 86.6% were free of any systemic diseases. They discovered that as the dosage of Botox was raised, the change in angle of deviation increased. Higher doses were more successful at reducing PD and strabismus, but lower doses were less effective at improving the degree of exotropia [8]. However, the doses applied in this study were like those applied in other investigations. The doses utilized by Merino et al. [14] ranged from 2.5 to 22.5 IU per muscle. Within 10 PD rectification, the

overall effectiveness rate was 28.9%. While the lowest percentage of improvement was seen in those with significant amblyopia and sensory exotropia (only 20% improvement to 20 PD), basic exotropia (52.4% reaching deviation angle within 10 PD) had the highest rate. In our study, there was no any complication recorded in our patients. In the current study, botox injections significantly increased mean changes in squint angle compared to bilateral rectus muscle recession. The injection dose in our study ranged from 5 to 25 IU per muscle, following the angle of deviation. Although there are no clear guidelines for Botox doses to treat strabismus. SU et al. [15] found a substantial difference in the angle of deviation before and after injection or surgery, and at 6 months, the deviation after treatment was significantly less than the deviation before treatment in both groups. Deviation angle changed much more with BTA injection (12.20.8) than in surgery after 6 months of treatment (9.20.3). In a case series of three patients, Stable orthotropia, stable 8-pd exotropia, and stable 18-pd exotropia were all noted by Owens et al. [16] at 2.5 years, 4 years, and 7 months, respectively. Skan et al. [17] reported the results of ten patients who underwent intraoperative BT during strabismus surgery and had big angle exotropia and esotropia. After an

average of 14 months of follow-up, they discovered that 70% of the patients had alignment within 10 pd of esotropia or exotropia. Khan [18] also examined the outcomes of eight patients who had concurrent intraoperative BT injections into the medial and lateral rectus muscles during a two-muscle horizontal rectus procedure. There was residual esotropia of less than one degree in six of the eight individuals. Thus, it was decided that this process was both secure and efficient. In addition to, The % net change in deviations significantly increased between 7 and 30 days after BT injection, according to Minguini et al. [19], although this effect did not last for more than three months. Both groups had the same initial post-operative measurement's percentage net change as compared to the measurement from the previous visit. Final deviations for 72% of patients were less than or equal to 10 PD, demonstrating a satisfactory overall success rate for surgery. Finally, BT has the potential to momentarily impact the extraocular muscles. Additionally, as previously mentioned, there is a substantial tendency for abnormalities to return in BT-treated individuals, which was also seen in our investigation, in sensory absence and binocularity motor. However, in children with fusion potential, BT therapy is likely to have an impact on long-term ocular alignment [20].

5. Conclusion

In the treatment of basic exotropia, Botox injection is effective but the study has limitations as the period of follow up was relatively short for only one year and the number of patients in both groups was relatively small. So, Botox injection for basic XT is recommended in cases in which surgery postponed for any reason.

References

1. Kaur, K., Gurnani, B. *Exotropia*. *InStatPearls* [Internet] 2022 Dec. 6. StatPearls Publishing; PMID 35201713.
2. Chougule, P., Kekunnaya, R. Surgical management of intermittent exotropia: do we have an answer for all. *BMJ Open Ophthalmology*. 2019; 4 (1): e000243.
3. Akay, A., Cakaloz, B., Berk, A.T., et al. Psychosocial aspects of mothers of children with strabismus. *J. of American Association for Pediatric Ophthalmology and Strabismus*. 2005; 9 (3): 268-273.
4. Spierer, O., Spierer, A. Unilateral lateral rectus recession is an effective surgery

- for intermittent exotropia in young children. *BMC ophthalmology*. 2021; 21 (1): 1-4.
5. Whitcup, S. The history of botulinum toxins in medicine: A thousand-year journey, in: Whitcup, S. & Hallett, M. (eds.) *Botulinum Toxin Therapy*. Springer, Cham. 2019; 3-10
 6. Scott, A. Botulinum toxin injection into extraocular muscles as an alternative to strabismus surgery. *Ophthalmology*. 1980; 87 (10): 1044-1049.
 7. Scott, A., Magoon, E., McNeer, K., et al. Botulinum treatment of childhood strabismus. *Ophthalmology*. 1990; 97 (11): 1434-1438.
 8. Al Hemaidi, S., Sesma, G., Ahmad, K., et al. Efficacy of botulinum toxin injection in exotropia treatment. *Middle East African J. of Ophthalmology*. 2021; 28 (3): 164-168.
 9. Lennerstrand, G., Nordbø, O., Tian, S., et al. Treatment of strabismus and nystagmus with botulinum toxin type A: An evaluation of effects and complications. *Acta Ophthalmologica Scandinavica*. 1998; 76 (1): 27-30.
 10. Stockman, A., Dieltiens, M., Janssens, H., et al. Ocular neuromyotonia: case reports and literature review. *Strabismus*. 2018; 26 (3): 133-141.
 11. Millán, T., de Carvalho, K., Minguini, N. Results of monocular surgery under peribulbar anesthesia for large-angle horizontal strabismus. *Clinics*. 2009; 64 (4): 303-308.
 12. Samizadeh, S., De Boule, K. Botulinum neurotoxin formulations: Overcoming the confusion. *Clinical, cosmetic, and investigational dermatology*. 2018; 11: 273-287.
 13. Tamhankar, M. Eye movement disorders: third, fourth, and sixth nerve palsies and other causes of diplopia and ocular misalignment, in: Liu, G., Volpe, N. & Galetta, S. (eds.) *Neuro-Ophthalmology: Diagnosis and Management*. Elsevier, 2019: pp. 489-547.
 14. Merino, P., Vera, R., Mariñas, L., et al. Botulinum toxin for treatment of restrictive strabismus. *J. of Optometry*. 2017; 10 (3): 189-193.
 15. Su, H., Fu, J., Wu, X., et al. Comparison of Botulinum toxin type A with surgery for the treatment of intermittent exotropia in children. *BMC Ophthalmology*. 2022; 22 (1): 1-8.
 16. Owens, P., Strominger, M., Rubin P., et al. Large-angle exotropia corrected by intraoperative botulinum toxin A and monocular recession resection surgery. *J. of American Association for Pediatric Ophthalmology and Strabismus*. 1998; 2 (3): 144-146.
 17. Özkan, S., Topaloğlu, A. & Aydın, S. The role of botulinum toxin A in augmentation of the effect of recession and/or resection surgery. *J. of American Association for Pediatric Ophthalmology and Strabismus*. 2006; 10 (2): 124-127.
 18. Khan, A. Two horizontal rectus eye muscle surgery combined with botulinum toxin for the treatment of very large angle esotropia. A pilot studies. *Binocular Vision & Strabismus Quarterly*. 2005; 20 (1): 15-20.
 19. Minguini, N., de Carvalho, K., Bosso, F., et al. Surgery with intraoperative botulinum toxin-A injection for the treatment of large-angle horizontal strabismus: A pilot study. *Clinics*. 2012; 67: 279-282.
 20. McNeer, K., Tucker, M., & Guerry, C. Incidence of stereopsis after treatment of infantile esotropia with botulinum toxin A. *J. of Pediatric Ophthalmology & Strabismus*. 2003; 40 (5): 288-292.